

CASE REPORT

Periapical Granuloma

¹Anish Sebastian, ²Prasanth Panikar, ³Kasim Kota, ⁴Asika Sasi

ABSTRACT

Periapical granuloma is a relatively common lesion or growth consisting of a proliferating mass of granulation tissue and bacteria that form in response to dead tissue in the pulp chamber of the tooth. The death of the pulp may be due to extensive decay, deep restorations, or trauma to the tooth. It is considered a reactive inflammatory process resulting from chronic irritation originating from the root canal system of the affected root. Periapical granuloma mainly consists of granulation tissue with alveolar bone loss and a large number of T lymphocytes and monocytes/macrophages together with a small number of B lymphocytes and polymorpho-nuclear leukocytes.

Keywords: Dental caries, Dental granuloma, Periapical granuloma.

How to cite this article: Sebastian A, Panikar P, Kota K, Sasi A. Periapical Granuloma. *Int J Prev Clin Dent Res* 2016;3(1):35-37.

Source of support: Nil

Conflict of interest: None

INTRODUCTION

In periapical granuloma (dental granuloma, chronic apical periodontitis), a tooth dies and may become slightly tender to touch, but shows little in the way of symptoms. The dead tooth may develop a low-grade infection around the root tip, which often follows an acute infection that has been inadequately drained and incompletely resolved.¹⁻³ It is the most common sequel of pulpitis or acute periapical periodontitis. The spread of pulpal infection is usually but not always in a periapical direction. The presence of lateral or accessory root canal opening on the lateral surface of the root at any level is a well-recognized anatomic deviation along which the infection may spread. It will give rise to a lateral granuloma or related inflammatory lesion.^{4,5} Most

lesions of periapical granuloma are discovered in routine radiographic examination, and it is the most common periapical radiolucency found in dental practice.

CASE REPORT

An 18-year-old boy reported to the dental clinic. His chief complaint was pain and swelling in the left mandibular posterior region (Fig. 1). A pulp test indicated necrosis of the pulp of the left mandibular first molar. Periapical radiograph showed a well-defined radiolucent lesion extending from the mesial to the distal root (Fig. 2). The widest horizontal diameter of the lesion on the film was approximately 3.2 mm. With the exception of the left mandibular first molar, all other teeth in the area of the lesion responded normally to the pulp tests. Root canal therapy was begun at this time and completed 2 weeks later. Recall radiograph taken after 8 months showed partial resolution of the lesion (Fig. 3) and after 18 months showed complete resolution of the lesion (Fig. 4). The patient is asymptomatic since then.

HISTOPATHOLOGY

Hyperemia and edema of the periodontal ligament with infiltration of the chronic inflammatory cells are seen. The inflammation and localized increased vascularity are associated with resorption of the supporting bone adjacent to this area. As the bone is resorbed, there is proliferation of both fibroblasts and endothelial cells with the formation of more tiny vascular channels and fibrils. Swollen endothelial cells line the new capillaries. It is a relatively homogenous lesion composed predominantly of macrophages, lymphocytes, and plasma cells. In early

¹Professor, ²Reader, ³Professor and Head, ⁴Postgraduate Student

^{1,4}Department of Conservative Dentistry, Kannur Dental College and Hospital, Kannur, Kerala, India

²Department of Oral and Maxillofacial Surgery, Kannur Dental College and Hospital, Kannur, Kerala, India

³Department of Oral Pathology, Kannur Dental College and Hospital, Kannur, Kerala, India

⁴Department of Conservative and Endodontics, Kannur Dental College and Hospital, Kannur, Kerala, India

Corresponding Author: Anish Sebastian, Professor Department of Conservative Dentistry and Endodontics Kannur Dental College and Hospital, Kannur, Kerala, India, e-mail: dranishsebastian@gmail.com

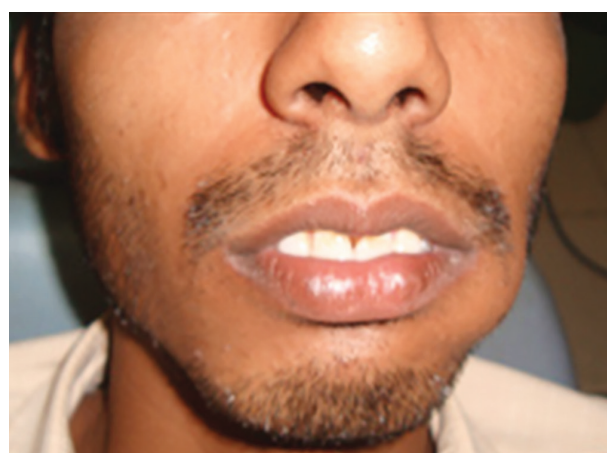

Fig. 1: Extraoral view

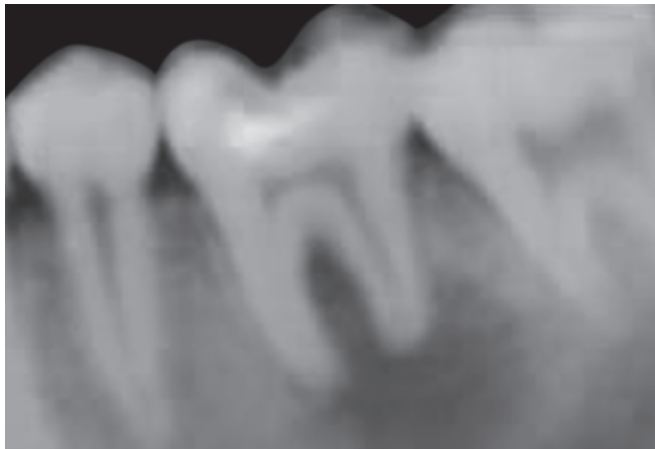


Fig. 2: Preoperative view

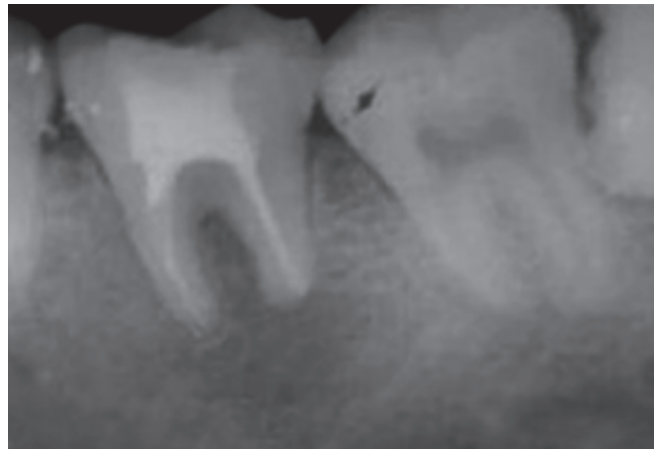

Fig. 3: Eight months postoperative

periapical granuloma, the epithelium is found close to the periodontal ligament. In course of time the epithelium undergoes proliferation by the inflammatory stimuli and shows an attempt to wall off the irritant coming out through the apical foramen, which becomes extensive and presents as sheets of stratified squamous epithelial cells as well as anastomosing cords.

TREATMENT AND PROGNOSIS

The treatment of periapical granuloma is extraction of the involved teeth or, under certain conditions, root canal therapy with or without subsequent apicoectomy. If left untreated, periapical granuloma may ultimately undergo transformation into an apical periodontal cyst through proliferation of epithelial rests in the area. In our patient, root canal treatment was performed.

DISCUSSION

The treatment of periapical granuloma mainly consists of root canal therapy with or without subsequent apicoectomy.⁶ If the initial conventional therapy is unsuccessful, endodontic retreatment represents the best approach for total elimination of bacteria and should be considered before periapical surgery. If left untreated, the periapical granuloma may ultimately undergo transformation into an apical periodontal cyst through proliferation of epithelial rests in the area. John et al⁷ evaluated periapically involved teeth treated endodontically to determine their rate of success. More important to the study, the rate of failure was also established, and the causes of failure were carefully examined. Nearly 95% of all endodontically treated teeth were successful. Lanolde⁸ suggested that whether a periapically involved tooth is affected by a granuloma or a cyst, nonsurgical endodontic therapy may be the treatment of choice. If the periapical lesion does not heal properly, an apicoectomy can be performed at a later date. Bhaskar⁹ in an attempt to explain nonsurgical resolution of cysts

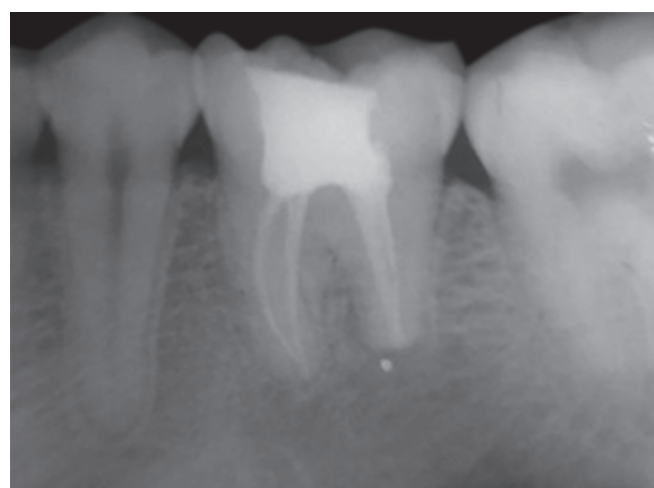


Fig. 4: Eighteen months postoperative

suggested that instrumentation of root canals through the apical foramen during treatment might result in a “transitory acute inflammation with epithelial destruction” or “subepithelial hemorrhage with ulceration of the epithelial lining.” He postulated that these mechanisms could destroy or disrupt the cyst epithelium, thus converting the cyst to a granuloma, which could resolve without surgical intervention. Thomas et al¹⁰ described two cases of periapical lesions treated by endodontic therapy. The canals were thoroughly debrided with sodium hypochlorite and calcium hydroxide paste placed in the canals. The access cavities were sealed with temporary restorations and patients were prescribed antibiotics. Four weeks postoperative it was observed that the lesions showed complete resolution, and it was suggested that the largeness of a lesion does not mandate its surgical removal and that even cyst-like lesions heal following conservative therapy.

CONCLUSION

Apical granuloma is an advanced stage of chronic apical periodontitis. It is the most common periapical

radiolucency found in dental practice. If cortical plate is perforated, healing begins with regeneration of the external cortical plate. It may usually show signs of healing within 1 year of treatment and in many instances as early as 2 to 4 months.

REFERENCES

1. Neville, BW.; Damn, DD.; Allen, CM.; Bouquout, JE. Pulp and periapical disease. Oral and maxillofacial pathology. 2nd ed. Philadelphia (PA): WB Saunders; 2002.
2. Stern MH, Drezen S, Mackler BF, Selbst AG, Levy BM. Quantitative analysis of cellular composition of human periapical granuloma. J Endod 1981 Mar;7(3):117-122.
3. Willoughby DA, Ryan GB. Evidence for a possible endogenous antigen in chronic inflammation. J Pathol 1970 Jul;101(3): 233-239.
4. Kuntz DD, Genco RJ. Localization of immunoglobulins and complement in persistent periapical lesions. IADR Progress Abst 1974;53:641.
5. Miller, WD. The micro-organisms of the human mouth. Philadelphia (PA): White Dental MFG Co.; 1890. p. 96.
6. Shafer, WG.; Hine, MK.; Levy, BM. A textbook of oral pathology. 4th ed. Philadelphia (PA): WB Saunders; 1983.
7. John I, James HS, Pierre M, Patrick B. Outcome of endodontic treatment and re-treatment. Endodontics 1956;22:1-22.
8. Lanolde ER. A new rationale for the management of periapical granulomas and cysts: an evaluation of histopathologic and radiographic findings. J Am Dent Assoc 1970 May;80(5): 1056-1059.
9. Bhaskar SN. Nonsurgical resolution of radicular cysts. Oral Surg Oral Med Oral Pathol 1972 Sep;34(3):458-468.
10. Thomas SB, Kandari AR, Abdul AA. Healing of large periapical lesions following calcium hydroxide endodontic therapy: two case reports and review of literature. Endodontology 2000;12:32-36.